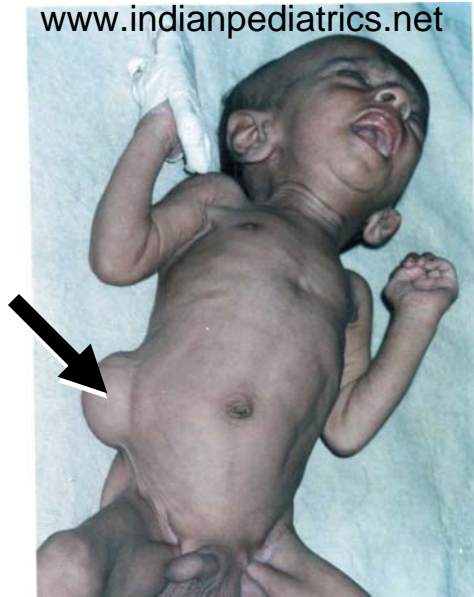

Lumbar Hernia

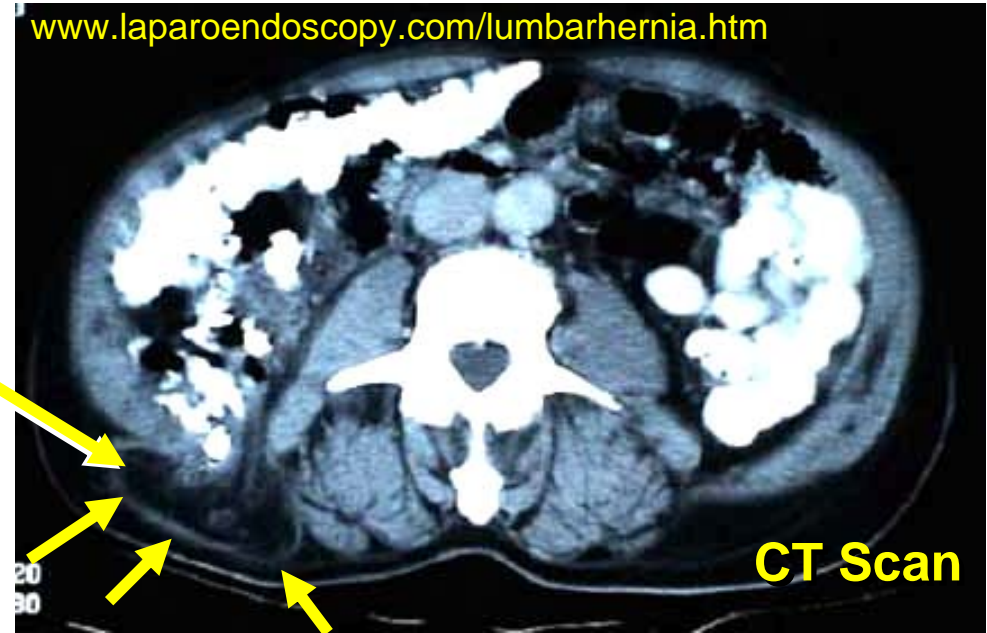
(lumbar triangle, Petit's triangle)

www.indianpediatrics.net

5-mo-old male



www.laparoendoscopy.com/lumbarhernia.htm



hernial sac

CT Scan

2006 Moore & Dalley COA

external oblique

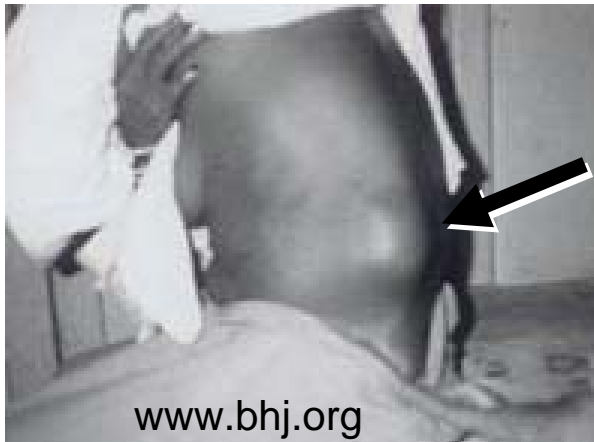lumbar triangle

latissimus dorsi

erector spinae

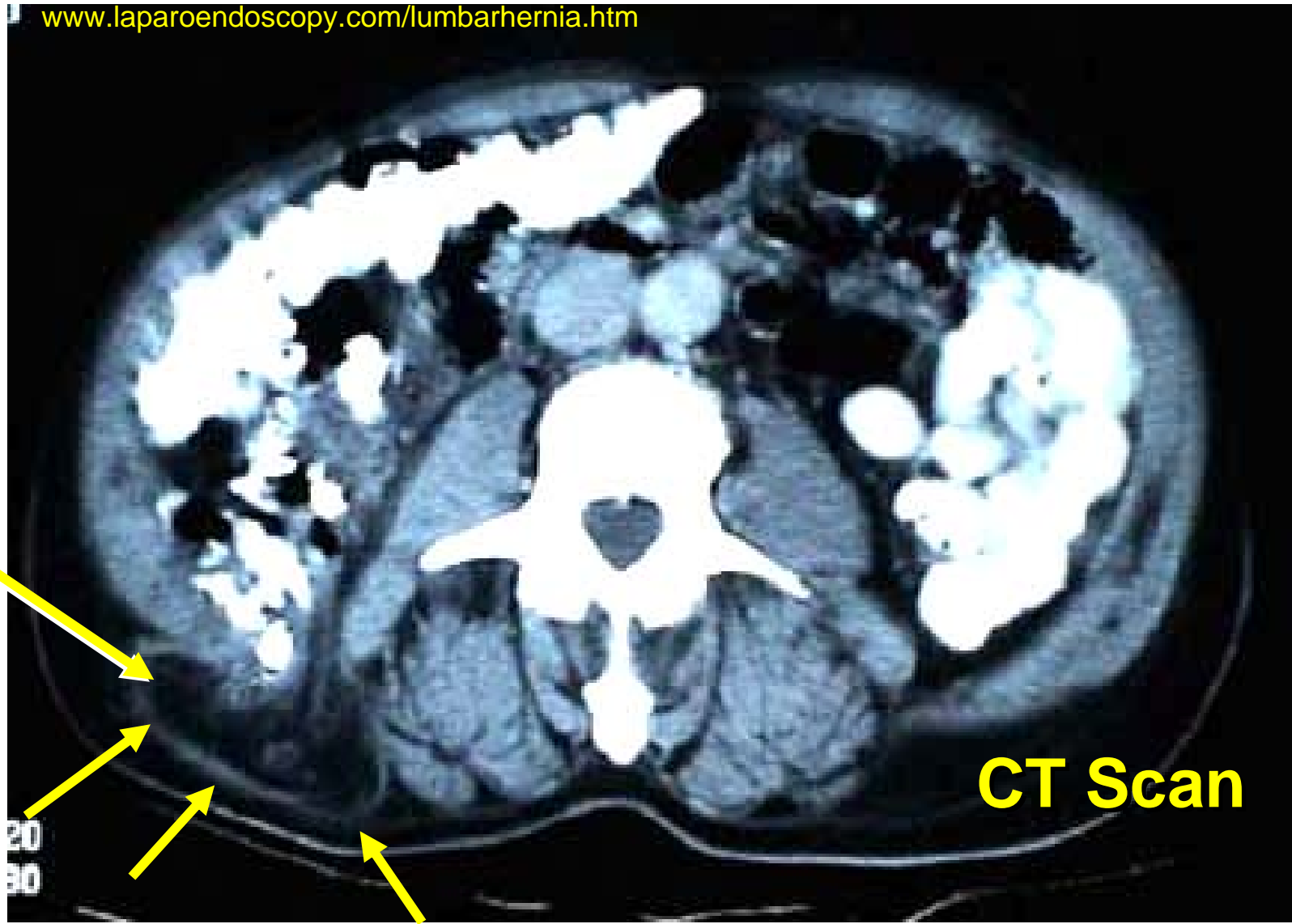
thoracolumbar fascia

60-yr-old female



www.bhj.org

www.laparoendoscopy.com/lumbarhernia.htm

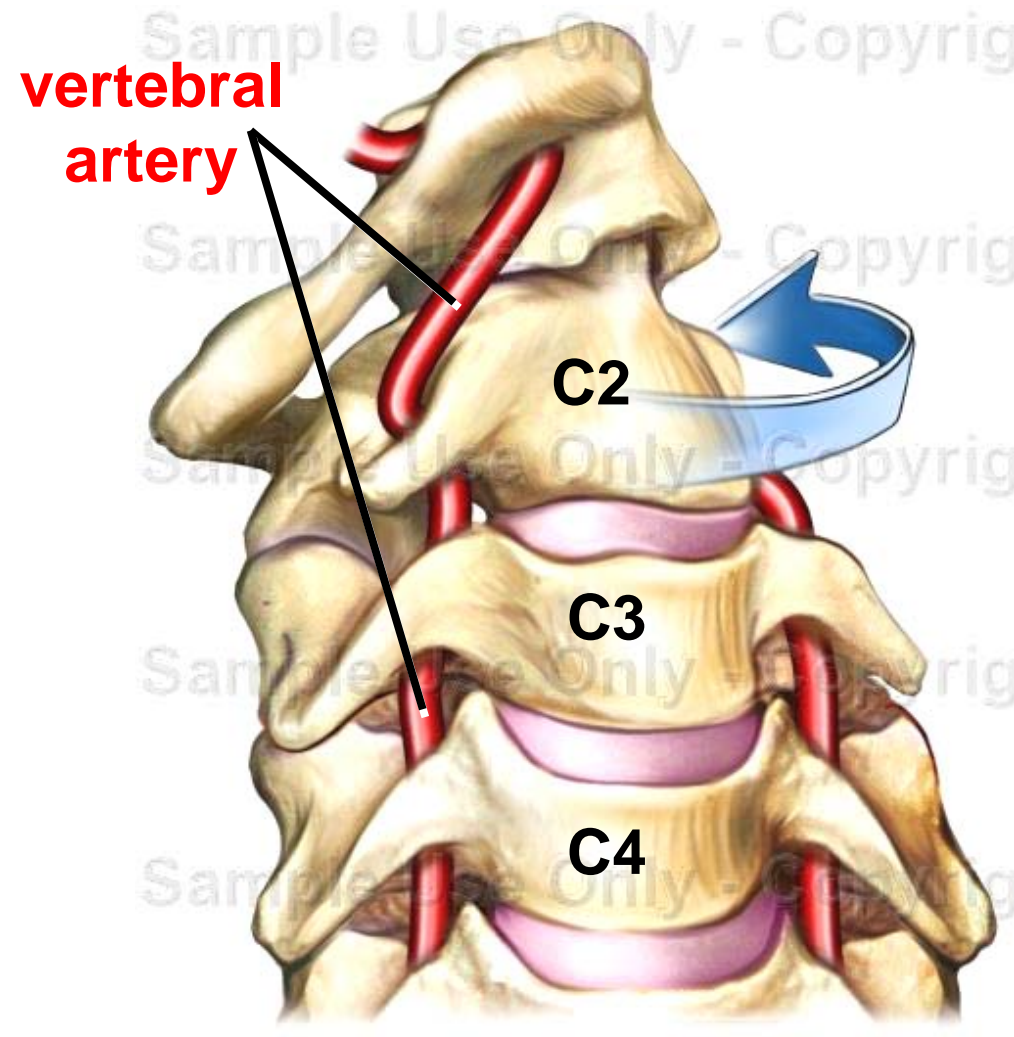
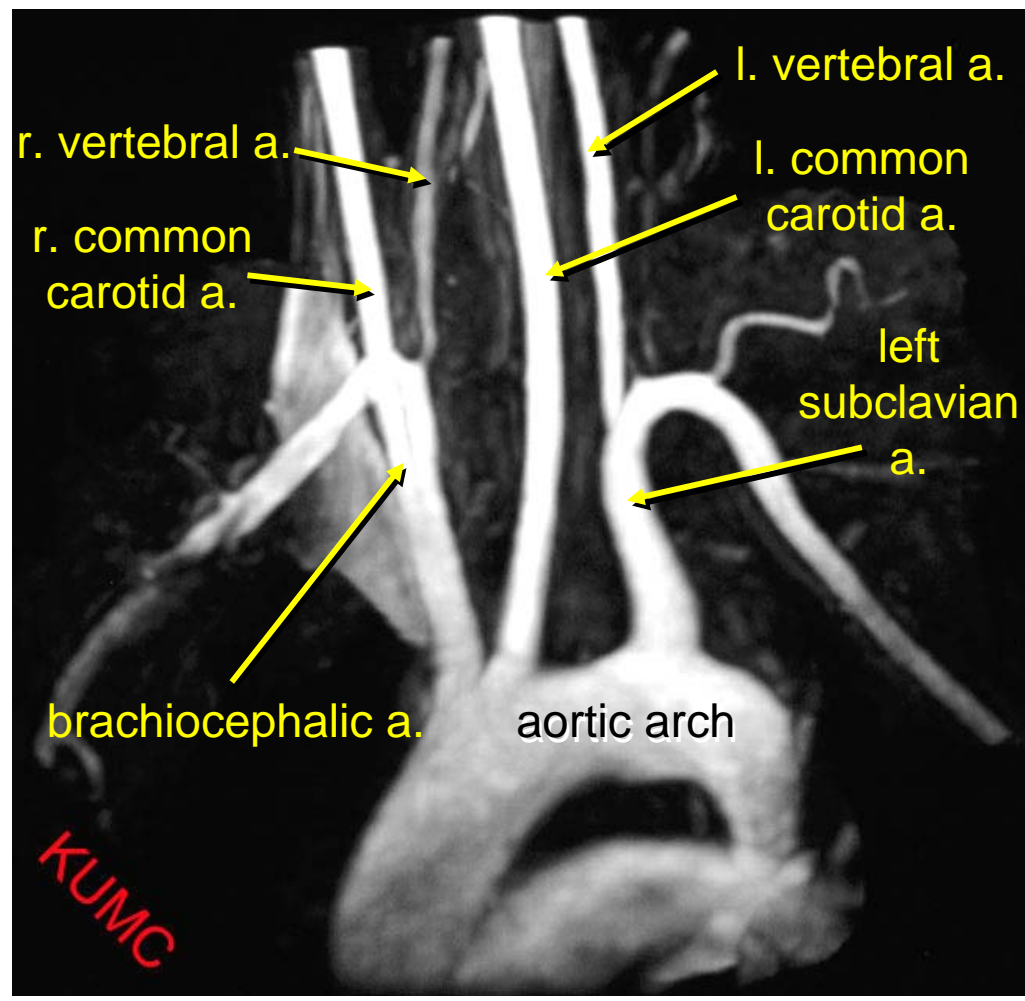


hernial sac

CT Scan

Vertebral Artery

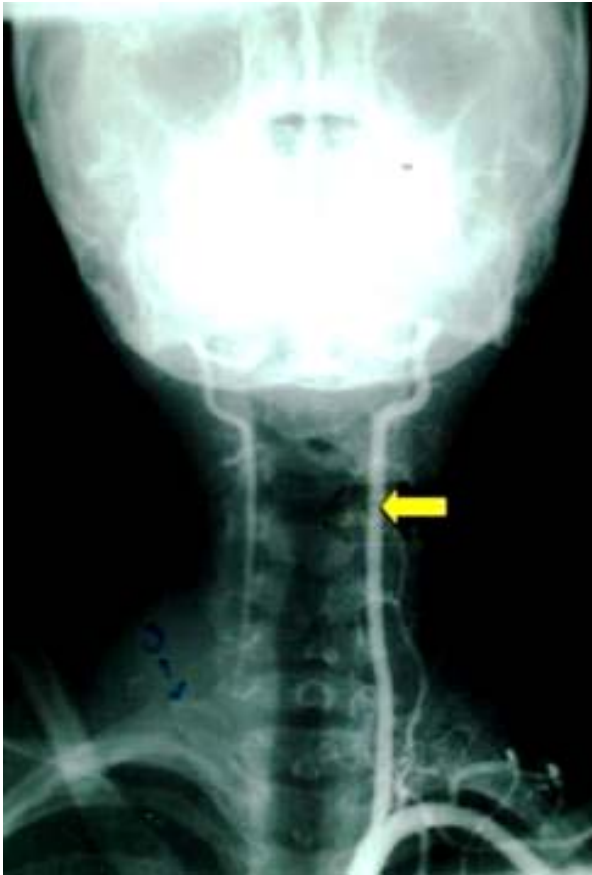rotational insufficiency



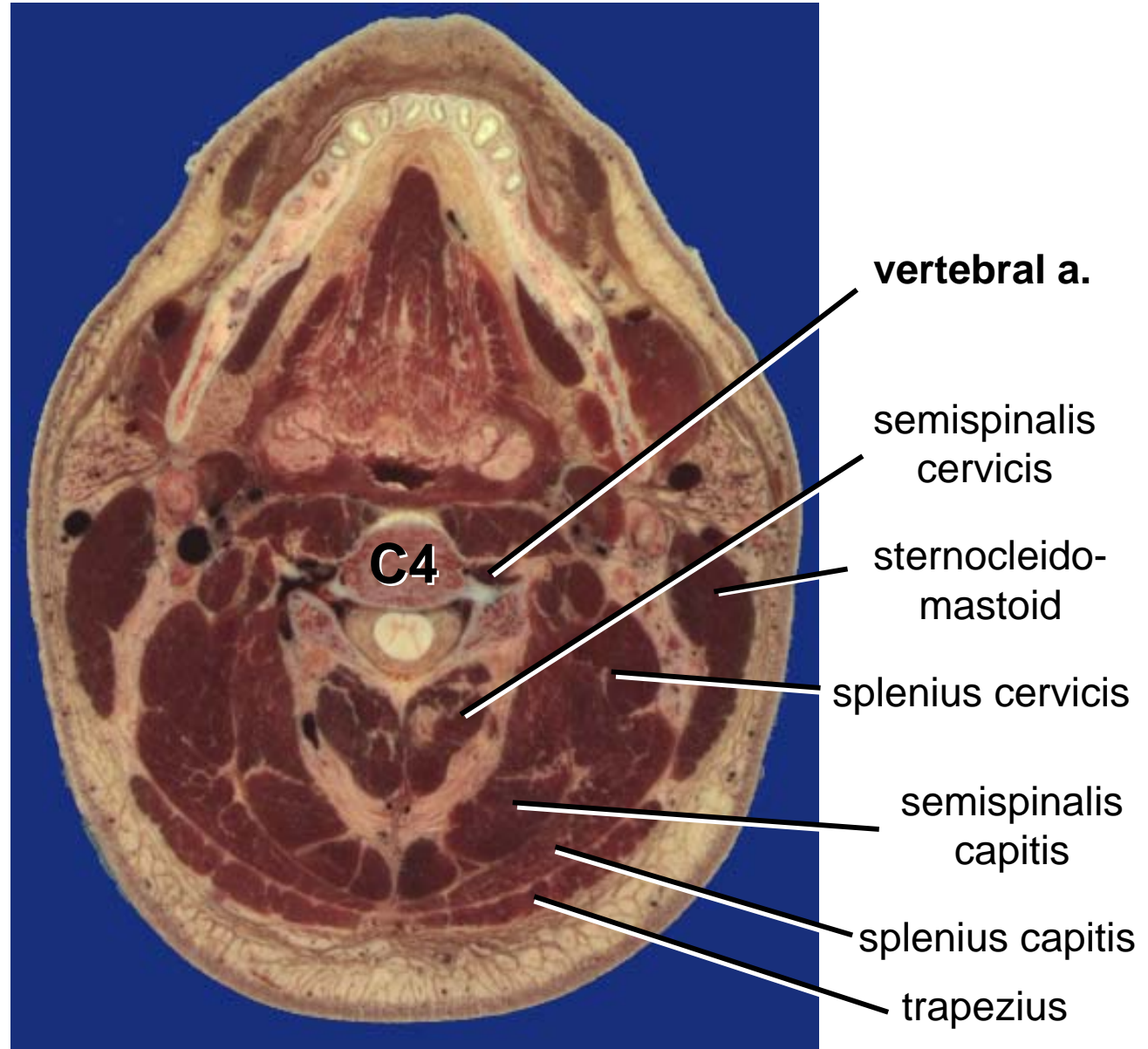
MRA — Magnetic resonance angiography
classes.kumc.edu/som/radanatomy/

doereport.com

Vertebral Artery

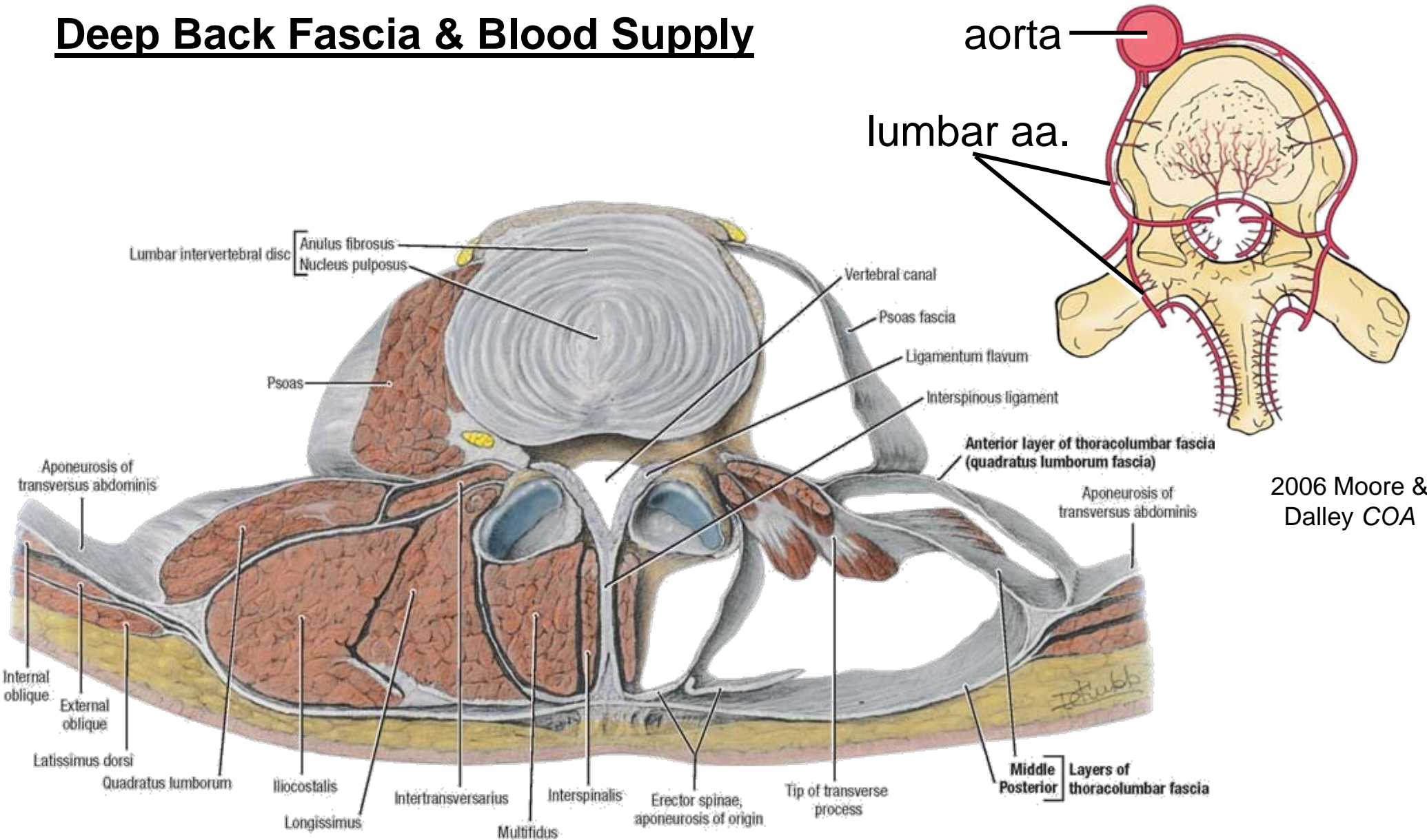


geocities.com/akramanatomy



www-medlib.med.utah.edu/WebPath

Deep Back Fascia & Blood Supply



2006 Moore & Dalley COA